

## Intracerebral Hemorrhage (ICH)

### Overview

Intracerebral hemorrhage (ICH) is a type of stroke caused by bleeding within the brain tissue itself – a very life-threatening situation. A stroke occurs when the brain is deprived of oxygen due to an interruption of its blood supply. ICH is most commonly caused by hypertension, arteriovenous malformations, or head trauma. Treatment focuses on stopping the bleeding, removing the blood clot (hematoma), and relieving the pressure on the brain.

### What is an intracerebral hemorrhage?

Tiny arteries bring blood to areas deep inside the brain (see Anatomy of the Brain). High blood pressure (hypertension) can cause these thin-walled arteries to rupture, releasing blood into the brain tissue. The blood collects and forms a clot, called a hematoma, which grows and causes pressure on surrounding brain tissue (Fig. 1). Increased intracranial pressure (ICP) makes a person confused and lethargic. As blood spills into the brain, the area that artery supplied is now deprived of oxygen-rich blood – called a stroke. As blood cells within the clot die, toxins are released that further damage brain cells in the area surrounding the hematoma.

An ICH can occur close to the surface or in deep areas of the brain. Sometimes deep hemorrhages can expand into the ventricles – the fluid filled spaces in the center of the brain.

### What are the symptoms?

If you experience the symptoms of an ICH, call 911 immediately! Symptoms usually come on suddenly and can vary depending on the location of the bleed. Common symptoms include:

- headache, nausea, and vomiting
- lethargy or confusion
- sudden weakness or numbness of the face, arm or leg, usually on one side
- loss of consciousness
- temporary loss of vision
- seizures

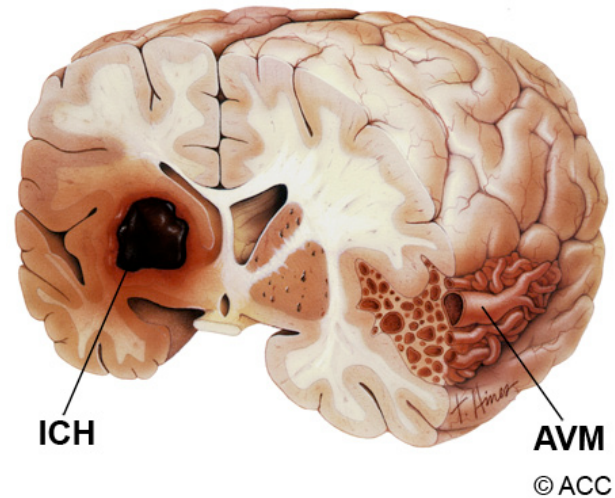


Figure 1. An intracerebral hemorrhage (ICH) is usually caused by rupture of tiny arteries within the brain tissue (left). As blood collects, a hematoma or blood clot forms causing increased pressure on the brain. Arteriovenous malformations (AVMs) and tumors can also cause bleeding into brain tissue (right).

### What are the causes?

- **Hypertension:** an elevation of blood pressure that may cause tiny arteries to burst inside the brain.
- **Blood thinner therapy:** drugs such as coumadin, heparin, and warfarin used to treat heart and stroke conditions.
- **AVM:** a tangle of abnormal arteries and veins with no capillaries in between.
- **Aneurysm:** a bulge or weakening of an arterial wall.
- **Head trauma:** fractures to the skull and penetrating wounds (gunshot) can damage an artery and cause bleeding.
- **Bleeding disorders:** hemophilia, sickle cell anemia, DIC, thrombocytopenia.
- **Tumors:** highly vascular tumors such as angiomas and metastatic tumors can bleed into the brain tissue.
- **Amyloid angiopathy:** a degenerative disease of the arteries.
- **Drug usage:** cocaine and other illicit drugs can cause ICH.
- **Spontaneous:** ICH by unknown causes.

## Who is affected?

Ten percent of strokes are caused by ICH (approximately 70,000 new cases each year). ICH is twice as common as subarachnoid hemorrhage (SAH) and has a 40% risk of death. ICH occurs slightly more frequently among men than women and is more common among young and middle-aged African Americans and Japanese. Advancing age and hypertension are the most important risk factors for ICH. Approximately 70% of patients experience long-term deficits after an ICH.

## How is a diagnosis made?

When you or a loved one is brought to the emergency room with an ICH, the doctor will learn as much about your symptoms, current and previous medical problems, current medications, family history, and perform a physical exam. Diagnostic tests help doctors determine the source and location of the bleeding.

**Computed Tomography (CT)** scan is a noninvasive X-ray to review the anatomical structures within the brain to see if there is any blood in the brain (Fig. 2). A newer technology called CT angiography involves the injection of contrast into the blood stream to view arteries of the brain.

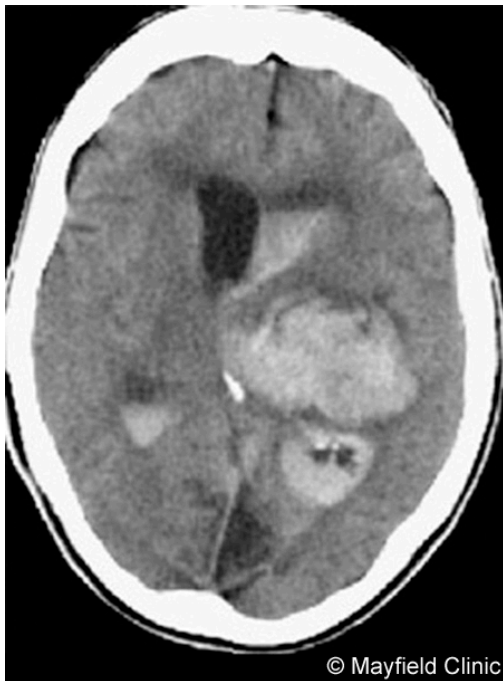

Figure 2. CT scan showing a large ICH.

**Angiogram** is an invasive procedure, where a catheter is inserted into an artery and passed through the blood vessels to the brain. Once the catheter is in place, a contrast dye is injected into the bloodstream and X-ray images are taken.

**Magnetic resonance imaging (MRI)** scan is a noninvasive test, which uses a magnetic field and radio-frequency waves to give a detailed view of the soft tissues of your brain. An MRA (Magnetic Resonance Angiogram) is the same non-invasive study, except it is also an angiogram, which means it examines the blood vessels as well as the structures of the brain.

## What treatments are available?

Once the cause and location of the bleeding is identified, medical or surgical treatment is performed to stop the bleeding, remove the clot, and relieve the pressure on the brain. If left alone the brain will eventually absorb the clot within a couple of weeks – however the damage to the brain caused by ICP and blood toxins may be irreversible.

Generally, patients with small hemorrhages (<10 cm<sup>3</sup>) and minimal deficits are treated medically. Patients with cerebellar hemorrhages (>3 cm<sup>3</sup>) who are deteriorating or who have brainstem compression and hydrocephalus are treated surgically to remove the hematoma as soon as possible. Patients with large lobar hemorrhages (50 cm<sup>3</sup>) who are deteriorating usually undergo surgical removal of the hematoma.

### Medical treatment

Blood pressure is managed to decrease the risk of more bleeding yet provide enough blood flow (perfusion) to the brain.

Controlling intracranial pressure is the biggest factor in the outcome of ICH. A device called an ICP monitor is placed directly into the ventricles or within the brain to measure pressure. Normal ICP is 20mm HG.

Removing cerebrospinal fluid (CSF) from the ventricles is a common method to control ICP. A ventricular catheter (VP shunt) may be placed in the ventricles to drain CSF fluid to allow room for the hematoma to expand without damaging the brain. Hyperventilation also helps control ICP. In some cases, coma may be induced with drugs to bring down ICP.

### Surgical treatment

The goal of surgery is to remove as much of the blood clot as possible and stop the source of bleeding if it is from an identifiable cause such as an AVM or tumor. Depending on the location of the clot either a craniotomy or a stereotactic aspiration may be performed.

**Craniotomy** involves cutting a hole in the skull with a drill to expose the brain and remove the clot. Because of the increased risk to the brain, this technique is usually used only when the hematoma is close to the surface of the brain or if it is associated with an AVM or tumor that must also be removed.

**Stereotactic aspiration** is a less invasive technique preferred for large hematomas located deep inside the brain. The procedure requires attaching a stereotactic frame to your head with four pins (screws). The pin site areas are injected with local anesthesia to minimize discomfort. A metal cage, which looks like a birdcage, is placed on the frame. Next, you undergo a CT scan to help the surgeon pinpoint the exact coordinates of the hematoma. In the OR, the surgeon drills a small hole about the size of quarter in the skull. With the aid of the stereotactic frame, a hollow needle is passed through the hole, through the brain tissue, directly into the clot. The hollow needle is attached to a large syringe, which the surgeon uses to suction out the contents of the blood clot.

## Recovery & prevention

Immediately after an ICH, the patient will stay in the intensive care unit (ICU) for several weeks where doctors and nurses watch them closely for signs of rebleeding, hydrocephalus, and other complications. Once their condition is stable, the patient is transferred to a regular room.

ICH patients may suffer short-term and/or long-term deficits as a result of the bleed or the treatment. Some of these deficits may disappear over time with healing and therapy. The recovery process may take weeks, months, or years to understand the level of deficits incurred and regain function.

## Clinical trials

Clinical trials are research studies in which new treatments—drugs, diagnostics, procedures, and other therapies—are tested in people to see if they are safe and effective. Research is always being conducted to improve the standard of medical care. Information about current clinical trials, including eligibility, protocol, and locations, are found on the Web. Studies can be sponsored by the National Institutes of Health (see [www.clinicaltrials.gov](http://www.clinicaltrials.gov)) as well as private industry and pharmaceutical companies (see [www.centerwatch.com](http://www.centerwatch.com)).

## Sources & links

If you have more questions or would like to schedule an appointment with one of our neurosurgeons, please call (515) 241-5760. Our offices are located on the Iowa Methodist Campus.

### Sources

1. Broderick JP, Zuccarello M, et al.: Guidelines for the Management of Spontaneous Intracerebral Hemorrhage. *Stroke* 30:905-915, 1999.
2. Fewel ME, Thompson BG, Hoff JT: Spontaneous Intracerebral Hemorrhage: a review. *Neurosurg Focus* 15: 2003.

### Links

National Stroke Association [www.stroke.org](http://www.stroke.org)

American Stroke Association  
[www.strokeassociation.org](http://www.strokeassociation.org)

[www.strokecenter.org](http://www.strokecenter.org)

## Glossary

**craniotomy:** surgical opening of a portion of the skull to gain access to intracranial structures and replacement of the bone flap.

**hematoma:** a blood clot

**hydrocephalus:** swelling in the brain due to a blockage of cerebrospinal fluid.

**hypertension:** high blood pressure.

**intracranial pressure (ICP):** pressure within the skull.

**ICP monitor:** a device used to measure intracranial pressure inside the brain.

**subarachnoid hemorrhage:** bleeding in the space surrounding the brain; may cause a stroke.

**transcranial doppler (TCD):** an ultrasound device used to measure blood flow through an artery.

**stereotactic:** a precise method for locating deep brain structures by the use of 3-dimensional coordinates.

**ventricles:** hollow areas in the center of the brain containing cerebrospinal fluid.

**ventriculoperitoneal (VP) shunt:** a catheter placed in the ventricle of the brain to drain excess cerebrospinal fluid.



updated > 2.2013

reviewed by > Mario Zuccarello, MD, Mayfield Clinic / University of Cincinnati Department of Neurosurgery, Ohio

Mayfield Certified Health Info materials are written and developed by the Mayfield Clinic & Spine Institute. We comply with the HONcode standard for trustworthy health information. This information is not intended to replace the medical advice of your health care provider. © Mayfield Clinic 1998-2013.